



**PATIENT**

Dazy Palmer

**SPECIES**

Canine

**BREED**

Miniature Schnauzer

**SEX**

Female Spayed

**AGE**

8.8 years

**WEIGHT**

10.6lbs

**INTERPRETED BY**

Maggie Machen Lamy,  
DVM, DACVIM  
(Cardiology)

**IMAGING PERFORMED BY**

Loetitia Saint-Jacques,  
LVT

**HOSPITAL NAME**

Pine Creek Veterinary  
Clinic

**REFERRING VET**

Dr. Mills

**INVOICE**

47728

**DATE**

4/29/26

**PRESENTING CLINICAL SIGNS**

History: Grade 2/6 heart murmur. Asymptomatic. Assess prior to anesthesia for cystotomy procedure.

**ECHOCARDIOGRAM FINDINGS**

2D, m-mode, color flow and doppler imaging is available. Mild mitral valve leaflet thickening with no obvious prolapse into the left atrial lumen. No mitral regurgitation is identified. Normal left atrial dimension. Normal LV diameter with normal myocardial function. The tricuspid valve appears subjectively normal. No TR. The right heart is normal. No overt evidence of pulmonary arterial hypertension. The pulmonic and aortic valves are normal in morphology and mobility. No aortic abnormalities identified, with normal outflow velocity. Normal pulmonic outflow velocities. No aortic insufficiency. Trace pulmonic insufficiency. No pericardial or pleural effusion noted. No cardiac tumors observed.

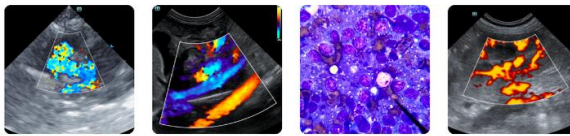
**CARDIAC CHART**

CANINE CARDIAC PARAMETERS	MR VMAX (m/s)	TR VMAX (m/s)	LA/AO (Boon method)	LA/AO (Heart Base; Swe)	FS (%)	EF (%)	EPSS (cm)
NORMAL PARAMETER	4.5-5.5	<2.7	1.3	<1.6	28-40	40-100	<0.6
PATIENT	NA	NA	NM	1.3	38	71	0.32
CANINE CARDIAC PARAMETERS	HR (BPM)	AV VMAX (m/s)	PV MAX (m/s)	BODY WEIGHT (kg)	LA 2D short axis Base view (cm)	LVIDd Avg; 2D and m-mode short axis (cm)	LVIDs Avg; 2D and m-mode short axis (cm)
NORMAL PARAMETER	50-100	0.7-1.7	0.7-1.6	BELOW	BELOW	BELOW	BELOW
PATIENT	NM	1.7	1.2	4.8	1.6	2.6	1.5
*Normal chamber parameters expressed as a mean value (SD)				3	1.27 (5.3)	2.46 (2.46)	1.36 (5.5)
<b>BODY WEIGHT DEPENDENT PARAMETERS</b>				5	1.40 (4.5)	2.74 (5.2)	1.60 (4.7)
<i>*Note: All measurements based upon multi-modal images and methods. An average value is reported.</i>				10	1.50 (3.8)	3.27 (3.5)	2.06 (3.1)
				15	1.83 (2.0)	3.71 (2.4)	2.43 (2.1)
				20	2.02 (1.9)	4.14 (2.2)	2.80 (2.0)
				25	2.18 (2.4)	4.48 (2.9)	3.10 (2.5)
				30	2.33 (3.3)	4.83 (3.9)	3.39 (3.4)
				35	2.48 (4.3)	5.17 (5.0)	3.69 (4.5)
				40	2.62 (5.2)	5.48 (6.1)	3.96 (5.4)
				50	2.88 (7.1)	6.07 (8.3)	4.46 (7.4)

**INTERPRETATION OF THE FINDINGS & FURTHER RECOMMENDATIONS**

Overtly normal cardiac structure and function with no cause of a murmur identified. No significant valvular insufficiencies were noted and no structural issues identified. In the absence of significant volume changes (dehydration or anemia), other possibilities include a physiologic flow murmur only present with elevated heart rates, or a small flow abnormality not seen here. Should the murmur persist/progress in the future, it is reasonable to monitor periodically via recheck echocardiography in the future.

No cardiac medications are indicated at this time. Prognosis is open. Monitor for any



**PATIENT**

development of cough, labored breathing or exercise intolerance.

Dazy Palmer

No cardiac contraindication for general anesthesia.

**SPECIES**

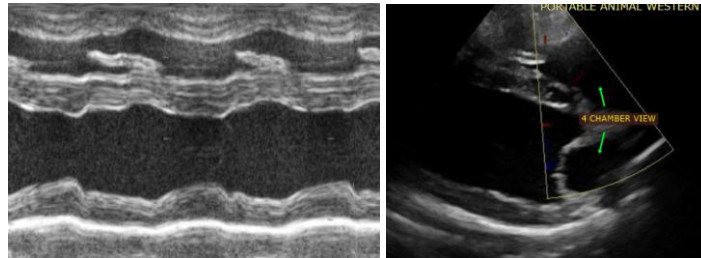
Canine

Recommend recheck echocardiogram in 12-18 months to reassess murmur origin and screen for development of concurrent cardiac disease that the preexisting murmur may mask.

**BREED**

Miniature Schnauzer

**IMAGES**



**SEX**

Female Spayed

**AGE**

8.8 years

**The information and recommendations provided are based on the images presented by the referring veterinarian. No evaluation can be communicated regarding pathology that was not visible in the image/video clips provided.**

**WEIGHT**

10.6lbs

Thank you for this referral. This report was generated using transcription software, and minor dictation errors may be present. If the clinical or image interpretation does not parallel your findings or if I can be of any further assistance, please contact me.

**INTERPRETED BY**

Maggie Machen Lamy,  
DVM, DACVIM  
(Cardiology)

**Maggie Machen Lamy, DVM**  
**Diplomate of the American College of Veterinary Internal Medicine (Cardiology)**  
info@sonopath.com

**IMAGING  
PERFORMED BY**

Loetitia Saint-Jacques,  
LVT

**HOSPITAL NAME**

Pine Creek Veterinary  
Clinic

**REFERRING VET**

Dr. Mills

**INVOICE**

47728

**DATE**

4/29/26